

# Pulmonary Thromboembolism Followed by Deep Vein Thrombosis In A Young Man With G6PD Deficiency After ChAdOx1 nCoV-19 Vaccine Administration

Hamidreza Zaheri<sup>1</sup>, Amirhossein Saeidi<sup>1</sup>, Mohammadhossein Banitorfi<sup>1</sup>, Zahra Sadat Rouhani<sup>2</sup>, Atefeh Abedini<sup>2</sup>, Arda Kiani<sup>3\*</sup>

<sup>1</sup>Abadan University of medical science, Tehran, Iran. <sup>2</sup>Chronic Respiratory Diseases Research Center, National Research Institute of Tuberculosis and Lung Disease (NRITLD), Shahid Beheshti University of Medical Sciences, Tehran, Iran. <sup>3</sup>Tracheal Diseases Research Center, National Research Institute of Tuberculosis and Lung Diseases (NRITLD), Shahid Beheshti University of Medical Sciences, Tehran, Iran.

## ARTICLE INFO

### Case Report

**VacRes, 2021**

Vol. 8, No.1, 88- 91

Received: January 04, 2022

Accepted: January 25, 2022

Pasteur Institute of Iran

### \*Corresponding Author:

Arda Kiani;

Tracheal Diseases Research Center,  
National Research Institute of  
Tuberculosis and Lung Diseases  
(NRITLD), Shahid Beheshti University  
of Medical Sciences, Tehran, Iran.

**Email:** ardakiani@yahoo.com

**Tel/Fax:** +98 912 254 4510

**KEYWORDS:** AstraZeneca,

Thromboembolism, vaccine, DVT

## ABSTRACT

Recently the term vaccine-induced immune thrombotic thrombocytopenia (VITT) used for individual which have thrombotic phenomena followed by ChAdOx1 nCoV-19 vaccine (AstraZeneca) administration against SARS coronavirus. Here we report the 27 years old healthy male and known case of G6PD deficiency which come to emergency department with progressive right calf swallow from 12 days ago and hemoptysis from a day ago. he mentioned he had administrated First dose of AstraZeneca vaccine for 3 weeks ago. He admitted with suspected pulmonary thromboembolism (PTE) followed by Deep vein thrombosis (DVT). In color Doppler study there are dilation in right calf vein with elevated lab measurement d-dimer indicated DVT also in computed tomography angiography (CTA) there are some evidence of filling defect in left pulmonary branch and right inferior lobar artery which represent to PTE.

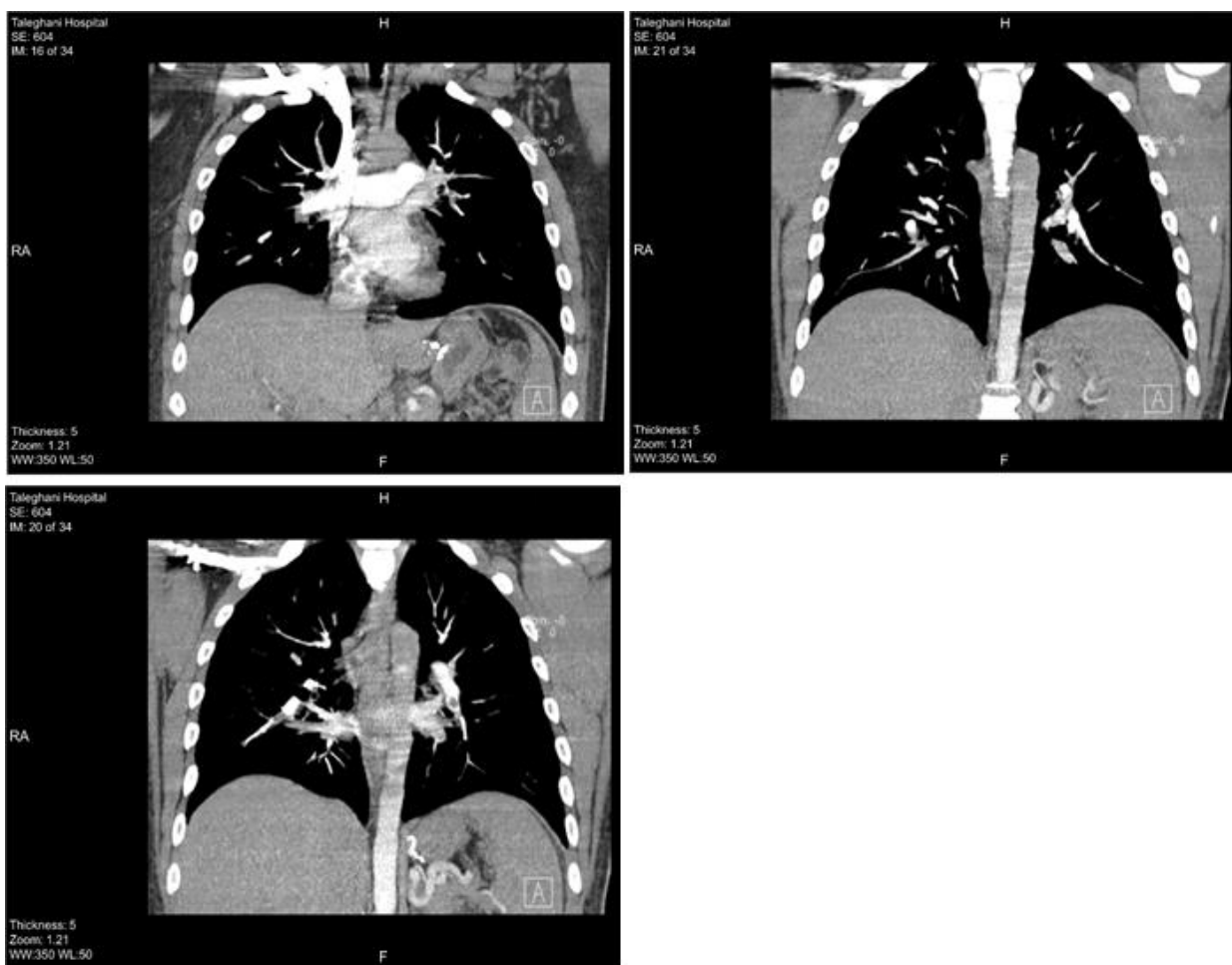### Citation:

## CASE DESCRIPTION

Here we present A 27-year-old young healthy man with a known case of G6PD deficiency, with pain in his right calf, from twelve days earlier and hemoptysis from one day earlier who was admitted in Taleghani Hospital in Abadan (Iran) for further work-up to rule out pulmonary thromboemboli and deep vein thrombosis. Symptoms had been initiated ten days after the administration of first dose of ChAdOx1 nCoV-19 vaccine (AstraZeneca). The pain was more severe at nights and involved whole part of the calf and became aggravated with exercise and activity. Hemoptysis was with flecks of blood in sputum. His past medical history indicated gastric bypass surgery in previous year as a treatment for Grade III fatty liver disease and obesity. He had no history of bleeding nor recent thrombotic accident.

In his social history, he mentioned smoking cannabis and cigarettes (one and half pack per day) since approximately five years ago. He was also using Tramadol tablet (50mg per day) since a year earlier. In his family history, his brothers also had cases of G6PD deficiency. The remarkable findings in his

physical examination were tenderness in right calf and hemoptysis. In his first day of hospital admission, Heparin (1600 IU per hour) was initiated for suspected vein thrombosis (VT). Color doppler sonography for his right lower limb (Venous system) was performed to confirm the diagnosis which demonstrated dilation and loss of compressibility in superficial femoral vein (SFV; saphenous vein) and popliteal vein (PV), indicating extensive acute thrombophlebitis. Computed Tomography Angiography (CTA) indicated filling defect in left pulmonary artery with developing to inferior lobar branch and right inferior branch which propounded PTE (Fig. 1). Three plus Qualitative Reactive Protein (CRP) measurement was also achieved. Peripheral Blood Smear (PBS) showed normal size, normochromic and normal morphology red blood cells without schistocytes, normal white blood cell count and morphology with left shift till band cell production stage.



**Fig. 1.** Filling defect is seen in the left pulmonary branch extending to the lower lobar branch and also in the right lower lobar branch extending to the sub-segmental branches.

Moreover, urine analysis showed slight hemoglobinuria. Second day Heparin was prescribed due to elevation in active Partial Thromboplastin Time (aPTT) and the patient started taking Rivaroxaban (15mg twice per day) and two units of Fresh Frozen Plasma (FFP) was ordered for him. Blood test

revealed thrombocytopenia ( $79 \times 10^3/\text{mm}^3$ ), elevated D-dimer test and marginally increase in alanine aminotransferase (Table 1). Echocardiography was also done for suspected right heart dysfunction, which the result was normal. Next day, a negative RT-PCR result rejected probable COVID-19.

**Table 1.** Laboratory results of a patient presenting with VITT; (ER; Emergency room/ HA; Hospital Admission/ PT; Prothrombin Time/ PTT; Partial thromboplastin time/ INR; International normalized ratio/ AST; Aspartate transaminase/ ALT; Alanine transaminase/ ALK-P; Alkaline phosphatase/ CRP; C-Reactive Protein/ CK-MB; Creatine Kinase-MB/ BUN; Blood urea nitrogen/ Cr; Creatinine/ LDH; Lactate dehydrogenase).

Time line Lab data	ER admission	Day2 HA	Day3 HA	Day4 HA	Day5 HA	Day6 HA	Day7 HA	Day8 HA	Day9 HA	Day10 HA
Hemoglobin (Ref: 14-18) (g/dl)	13.1	11.8	11.3	11.7	11.8	11.8	12	11.7	12.1	12.5
Platelet count (Ref: 130-400) ( $\times 10^3/\text{mm}^3$ )	101	79	141	137	141	140	153	164	186	166
Leukocyte (Ref: 4-10) (neut%) ( $\times 10^3/\mu\text{L}$ )	7.6 (85%)	9.67 (59%)	7.7 (88%)	7.8 (57%)	8.38 (69.3)	9.3 (69%)	10.03 (67%)	11.67 (70.2)	8.99 (61%)	8.65 (61%)
D-dimer (Ref: $\leq 250$ ) (ng/mL)	-	3327	-	3401	-	3412	-	3397	-	3456
PT (Ref: 11-13) (seconds)	18	25.6	16.8	17.7	17.6	21.2	14.8	21.5	19.3	21
INR (Ref: $\leq 1.1$ )	1.7	2.6	1.4	1.5	1.5	1.8	1.15	2.0	1.8	2.1
PTT (Ref: 25-45) (seconds)	90	$\geq 120$	42	44	45	36	35	56	60	56

AST (Ref: 0-37) (IU/L)	-	32	-	-	-	-	-	-	-	-
ALT (Ref: 0-41) (IU/L)	-	69	-	-	-	-	-	-	-	-
ALK-P (Ref: 80-306) (U/L)	-	206	-	-	-	-	-	-	-	-
Total Bilirubin (Ref: 0.2-1.2) (mg/dl)	-	0.9	-	-	-	-	1.3	1.2	-	-
Direct Bilirubin (Ref: 0.1-0.3) (mg/dl)	-	0.3	-	-	-	-	0.5	0.5	-	-
CRP	3+	-	-	-	-	-	-	-	-	-
Troponin T	Negative	-	Negative	-	-	-	-	-	-	-
CK-MB (Ref: ≤24) (U/L)	15	-	-	-	-	-	-	-	-	-
RT-PCR Covid19	-	-	-	-	Negative	-	-	-	-	-
Anti-Hcv ELISA/ HBsAg ELISA/ HIV1-2 ELISA	-	-	-	Negative	-	-	-	-	-	-
BUN (Ref: 8-20) (mg/dl)	17	15	-	18	17	18	14	15	18	18
Cr (Ref: 0.7-1.4) (mg/dl)	0.9	1.0	-	1.0	1.1	1.0	1.0	1.0	0.9	1.0
LDH (Ref: 200-500) (IU/L)	-	514	-	-	-	-	-	-	-	-
Retic count (Ref: 0.5%-1.5%)	-	0.5%	-	-	-	-	-	-	-	-

The patient was hospitalized for ten days, Rivaroxaban (15mg BID) with initiation vitamin C were ordered for him. Symptoms were improved gradually while pain and swelling in the right calf were also reduced. In all those ten days, the patient was oriented and reliable. His vital signs were all in normal range with no dyspnea. The patient was discharged with Rivaroxaban (15mg twice a day), which changed to 20 mg daily after one month. As follow up, color doppler ultrasonography was performed which revealed normal popliteal vein and localized SFV partial thrombosis.

Today vaccination has become the main part of controlling COVID-19 pandemic [1]. According to recent studies, the administrations of COVID-19 vaccine produced by AstraZeneca have indicated some major thrombosis phenomenon [2]; most of them are grouped into sub massive thrombosis. In this case report, we presented a young healthy man without any risk factors of thrombosis and any past thrombosis event, who came in with massive bilateral PTE and parenchymal infarction in spiral computed tomography of the chest (Fig. 2).

## DISCUSSION

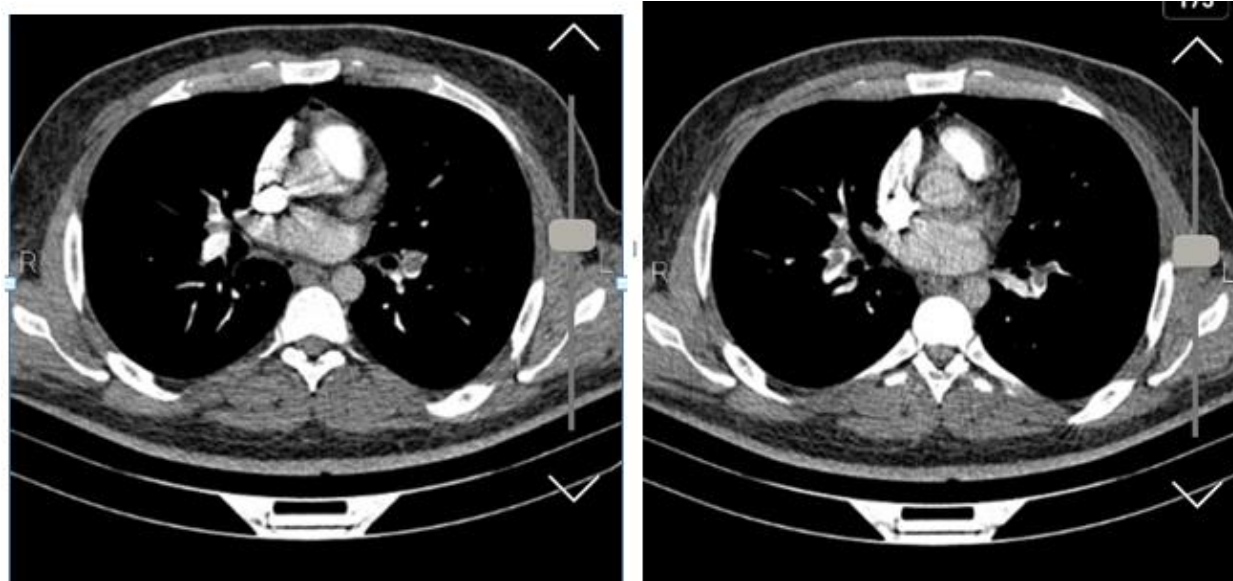


Fig. 2. Parenchymal infarction in spiral computed tomography of the chest.

He was hospitalized for ten days, and Rivaroxaban tablet was prescribed for him. The Patient was discharged in good health condition and was followed up by a pulmonologist every month. Previously, thrombosis event was considered as a life-threatening event mostly for females, whereas it can occur in males too. This case was reported to document a potential serious side effect of AstraZeneca's COVID-19 vaccine which is now an important parameter for controlling COVID-19 pandemic.

#### CONFLICT OF INTERESTS

The authors declare that there is no conflict of interest.

#### REFERENCES

1. Wolf ME, Luz B, Niehaus L, Bhogal P, Bänzner H, Henkes H. Thrombocytopenia and intracranial venous sinus thrombosis after "COVID-19 vaccine AstraZeneca" exposure. *Journal of clinical medicine*. 2021;10(8):1599.
2. Franchini M, Liumbruno GM, Pezzo M. COVID-19 Vaccine-associated Immune Thrombosis and Thrombocytopenia (VITT): diagnostic and therapeutic recommendations for a new syndrome. *European Journal of Haematology*. 2021;107(2):173-80.